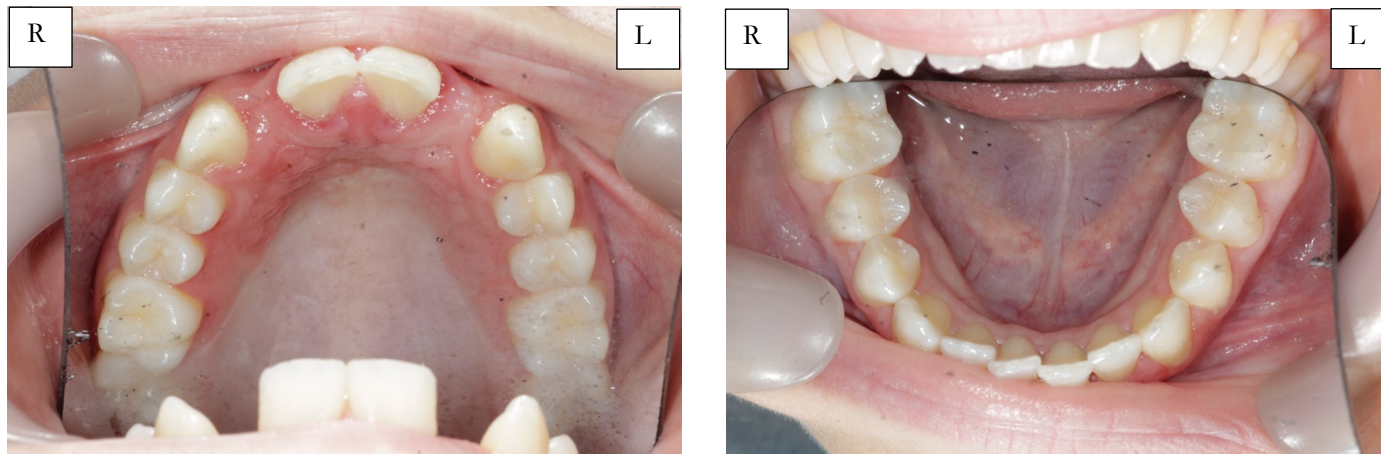
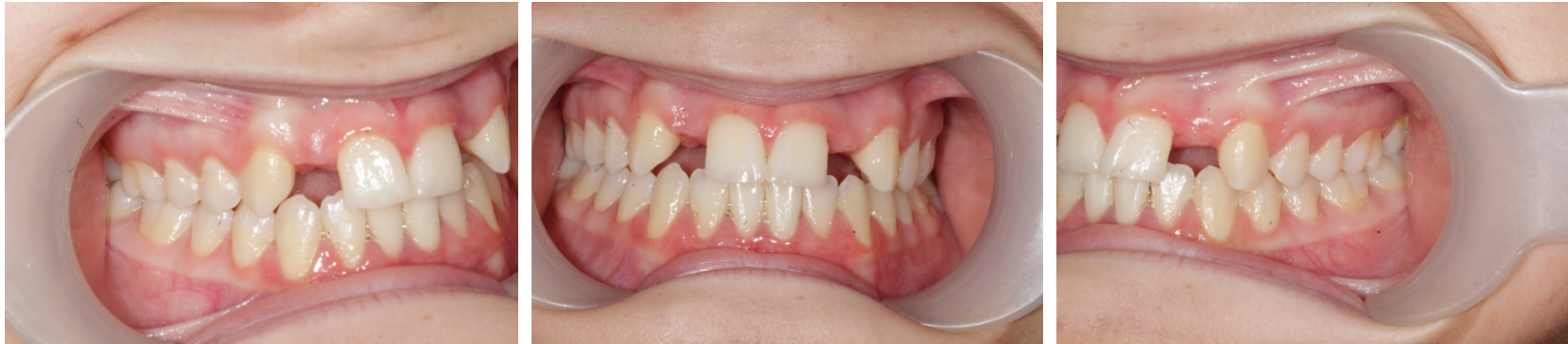
PATIENT DETAILS

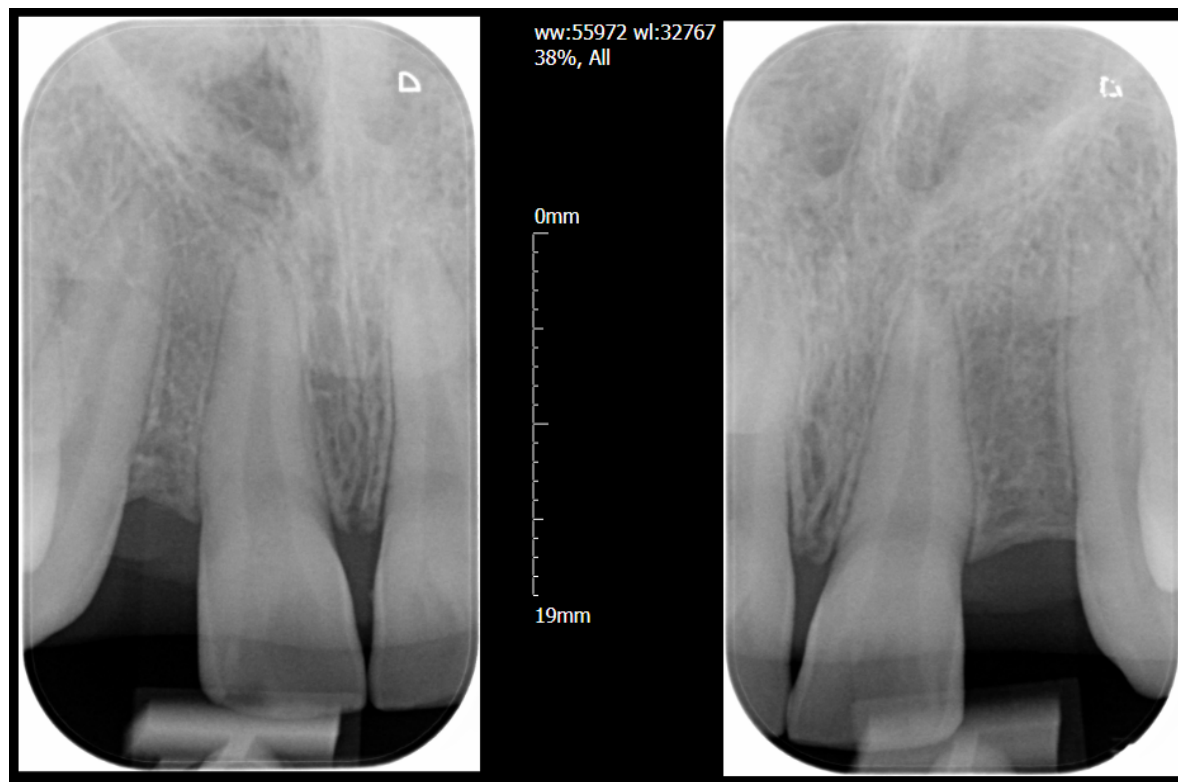
Patient	EI								
Gender	Female								
Age	16 years-old								
Complaint	Missing lateral incisors								
Medical history	NRMH Medications – Nil Allergies – None known								
Past Dental History	Regular dental attender DIET – low sugar intake OH – Moderate								
Social History	School, studying for GCSEs Non-smoker								
Extra Oral	No lymphadenopathy. No trismus. TMJ and muscles mastication normal Moderate height smile line								
Intra Oral Soft tissues	Refer to clinical photographs.								
Intra Oral Dental status	Refer to clinical photographs								
Periodontal status Plaque control: moderate, evidence of effective brushing but some plaque at gingival margins BPE: <table border="1" data-bbox="606 1361 987 1496"> <tr> <td>1</td> <td>1</td> <td>1</td> </tr> <tr> <td>1</td> <td>2</td> <td>1</td> </tr> </table>				1	1	1	1	2	1
1	1	1							
1	2	1							
Other information									

PHOTOGRAPHS



Note: Occlusal photos have been flipped account for them being taken in a mirror.

RADIOGRAPHS



PREFERRED TREATMENT PLANS

Please indicate what you would charge for the following:

1. Acrylic RPD replacing UL2,UR2
2. Co-Cr RPD replacing UL2,UR2
3. RRB. Wings on UL1,UR1 and pontics in positions UL2,UR2.
4. RRB's x 2; replacing UR2 (mesial cantilever from UR3) AND replacing UL2 (mesial cantilever from UL3)
5. Vacuum-formed orthodontic retainer

N.B. Please only provide responses IF you feel that you possess the clinical skills to provide the recommended item of treatment.