

Mrs Fat Face



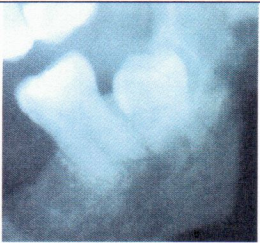
A 35 year old lady returns to your practice 3 days following surgical removal of the infected LL6 roots on an emergency clinic. Since the surgery she has developed extensive swelling of the face and feels very unwell.

What is your differential diagnosis?

How would you clinically assess this patient?

How will you manage this patient?

Mr Numb Lip



A 33 year old male patient attends with profound numbness of his lower lip following removal of an impacted wisdom tooth at the specialist clinic 2 days previously.

What is your initial management?

What warnings should the patient have received pre operatively?

Mrs Dribble



A patient attends for review 2 days following the removal of UR6 with colleagues at the weekend. She is complaining of discomfort over the right cheek and fluid coming out of her nose after drinking.

How would you investigate this case?

How would you manage the patient?